Prevalence of Sonographic Achilles Tendon, Patellar Tendon, and Plantar Fascia Abnormalities in Division I Collegiate Athletes From a Variety of Sports

Daniel M. Cushman, MD,*† Andrea Carefoot, MD,* Blake Corcoran, MD,‡ Leyen Vu, DO,‡ Michael Fredericson, MD,§ Cameron Fausett, MD,§ Masaru Teramoto, PhD, MPH, PStat,* and Sarah F. Eby, MD, PhD¶

Abstract

Objective: This study aimed to determine the prevalence of ultrasound abnormalities in the Achilles tendon, patellar tendon, and plantar fascia among a large cohort of collegiate student-athletes. **Design:** Observational cross-sectional study. **Setting:** Three Division I institutions. **Participants:** 243 student-athletes participated in this study. Exclusion criteria included those younger than 18 years or who underwent prior surgery/amputation of structures, including anterior cruciate ligament (ACL) surgeries with patellar tendon grafts. **Interventions:** Ultrasound examination of the Achilles tendon, patellar tendon, and plantar fascia of each leg was performed. An experienced sonographer reviewed each tendon video in a blinded manner, with a separate experienced sonographer separately reviewing to establish inter-rater reliability. **Main Outcome Measures:** The primary outcome measured was the presence of any sonographic abnormality including hypoechogenicity, thickening, or neovascularity. **Results:** Ultrasound abnormalities were identified in 10.1%, 37.2%, and 3.9% of all Achilles tendons, patellar tendons, and plantar fasciae, respectively. Abnormalities were significantly associated with the presence of concurrent pain for all structures ($P < 0.01$). Specifically, athletes with sonographic abnormalities were approximately 4 times [relative risk (RR) = 4.25; 95% confidence interval (CI), 2.05-8.84], 6 times (RR = 5.69; 95% CI, 2.31-14.00), and 5 times (RR = 5.17; 95% CI, 1.76-15.25) more likely to self-report pain in the Achilles tendon, patellar tendon, and plantar fascia, respectively. **Conclusions:** This multi-institutional study completed at 3 Division I institutions is the largest study of its kind to identify the prevalence of sonographic abnormalities in the Achilles tendon, patellar tendon, and plantar fascia among collegiate student-athletes of various sports.

Key Words: sonographic abnormality, patellar tendon, Achilles tendon, plantar fascia

(*Clin J Sport Med* 2023;00:1–7)

INTRODUCTION

Patellar tendinopathy, Achilles tendinopathy, and plantar fasciopathy are common conditions that prevent athletes from participating in practice and competition.[1–3] These conditions can be challenging to treat and can lead to time-intensive and costly interventions. Ultrasound is a cost-effective and accessible diagnostic tool for these 3 conditions. Tendon/fascia abnormalities on imaging are not essential for clinical diagnosis but are considered a risk factor for symptom development.[4,5] The term tendinopathy is an umbrella term describing clinical symptoms related to tendon overuse while tendinosis refers to histopathologic changes within the tendon that are often visible with imaging.[6,7]

Previous studies have proposed the use of ultrasound to detect tendon structural changes that could be associated with the development of tendinopathy to provide an opportunity for preventative training and rehabilitation programs.[8] To best develop such programs, it is necessary to identify the prevalence of, and associations with, these sonographic abnormalities—namely, thickening and hypoechogenicity (disordered tendon healing alters the structure of the tendon) and neovascularity (scattered vascular ingrowth from a healing tendon).[6] A variety of studies[9–11] have assessed these questions in smaller cohorts or in specific athletes such as asymptomatic endurance runners or elite football players. To date, this has not been systematically performed on a large cohort of collegiate student-athletes. This study aimed to determine the prevalence of ultrasound abnormalities in the

Submitted for publication December 29, 2022; accepted June 28, 2023.

*From the Departments of *Physical Medicine & Rehabilitation; and †Orthopaedics, University of Utah, Salt Lake City, Utah; ‡Washington State University, Cougar Health Services, Pullman, Washington; §Division of Physical Medicine & Rehabilitation, Department of Orthopedic Surgery, Stanford University, Palo Alto, California; and ¶Department of Physical Medicine & Rehabilitation, Harvard Medical School/Spaulding Rehabilitation Hospital, Boston, Massachusetts.*

This project was supported with support from the Pac-12 Conference's Student-Athlete Health and Well-Being Initiative. The content of this manuscript is solely the responsibility of the authors and does not necessarily represent the official views of the Pac-12 Conference or its members. Research reported in this publication was also supported by the National Center for Advancing Translational Sciences of the National Institutes of Health under Award Number UL1TR002538. The content is solely the responsibility of the authors and does not necessarily represent the official views of the National Institutes of Health.

The authors report no conflicts of interest.

Corresponding Author: Daniel M. Cushman, MD, 590 Wakara Way, Salt Lake City, UT 84108 (dan.cushman.work@gmail.com).

Supplemental digital content is available for this article. Direct URL citations appear in the printed text and are provided in the HTML and PDF versions of this article on the journal's Web site (www.cjsportmed.com).

Copyright © 2023 Wolters Kluwer Health, Inc. All rights reserved.

http://dx.doi.org/10.1097/JSM.0000000000001183

Copyright © 2023 Wolters Kluwer Health, Inc. Unauthorized reproduction of this article is prohibited.

Achilles tendon, patellar tendon, and plantar fascia among a large cohort of collegiate student-athletes of various sports. This study also aimed to identify associations between demographic and sport-related factors and the presence of these abnormalities.

METHODS

This multi-institutional study of 3 Division I institutions was approved by the primary author's institutional board. Student-athletes were approached in the preseason physical examinations to take part in this study, which included an ultrasound examination of the Achilles tendon, patellar tendon, and plantar fascia of each leg. Demographic information (see **File 1, Supplemental Digital Content**, http://links.lww.com/JSM/A387) was obtained through self-reported survey at the time of ultrasound scans. All student-athletes were eligible with the following exclusion criteria: (1) age younger than 18 years or (2) prior surgery/amputation to structures (including ACL surgeries with patellar tendon grafts; only the affected tendon/fascia was excluded in the statistical analysis). The sonographic scans were performed in a protocolized fashion with a 12 to 18 MHz linear probe (Logiq E9 R7, Sonosite PX, Sonosite X-porte, Konica Minolta Sonimage HS-1). They were directly supervised or performed by an experienced sports medicine physician (all with at least 5 years of post-training experience) who was blinded to subject demographics. Athletes were positioned supine with the knees bent at 90 degrees for the patellar tendon images, then fully extended and relaxed for patellar neovascularization measurements. The Achilles tendons were examined with the athlete prone with the ankle passively flexed to 0° dorsiflexion, then relaxed for the Achilles neovascularization and plantar fascia measurements. Approximately 10 seconds videos were saved in long-axis and short-axis of the tendons and long-axis only for the plantar fascia, with neovascularity performed using a previously validated method.[12] This resulted in a total of 20 videos per subject. Assessment of the videos was performed later by the primary author, blinded to any identifiable characteristics of the tendon/fascia under review, identifying the presence of hypoechogenicity (focal areas within the tendon), morphologic thickening[13–16] (altered shape of the tendon with increased width), and neovascularity using Doppler ultrasound (neovessels entering the tendon).[12] Thicknesses were measured (1) from the deep layer of the patellar tendon to the superficial as it is attached to the patella,[17] (2) at the maximum anteroposterior depth based on an axial video scan from the myotendinous junction to the insertion of the Achilles tendon, and (3) over the region of maximal thickness of the plantar fascia.[9] Inter-rater reliability was performed by comparing a random assessment of 20% of the images by a blinded secondary experienced sonographer. The presence of any abnormality was deemed "abnormal;" thus, tendons were compared either as "normal" or "abnormal" for reliability comparisons.

Data analysis was performed with Stata 17.0 (StataCorp LLC, College Station, TX) by a blinded statistician. Contingency tables were generated to summarize associations between ultrasound abnormality and current pain in the Achilles tendon, patellar tendon, and plantar fascia, including both right and left tendons/fasciae from each athlete. Tendons were analyzed individually. To account for possible correlated observations, a generalized linear model with binomial family and log link[18,19] was used to determine statistical significance and to calculate a relative risk (RR)[20,21] while choosing the clustered sandwich estimator of the variance to calculate standard errors.[22,23] Furthermore, logistic regression analysis, with the clustered sandwich estimator of the variance to calculate standard errors, was performed to identify associations to the presence of an abnormality, with the following independent variables: age, sex, body mass index, years in sport, and type of sport (categorized as explosive, running, skill-based, or aquatic). Inter-rater reliability was calculated by kappa values between raters.

RESULTS

A total of 243 subjects (486 potential tendons) were recruited, with demographic information seen in Table 1. Figure 1 displays the percentages of subjects who displayed at least one type of abnormality while Figure 2 shows histograms of structure thickness (mean thicknesses 4.04 ± 0.59, 4.29 ± 0.99, and 3.40 ± 0.60 mm for the Achilles tendon, patellar tendon, and plantar fascia, respectively). The prevalence of abnormalities is summarized in Table 2. Ultrasound abnormality was significantly associated with the presence of pain for the Achilles tendon, patellar tendon, and plantar fascia ($P < 0.01$; Table 3). Specifically, athletes with tendon abnormalities (hypoechogenicity, thickness, and/or neovascularity) were approximately 4 times [RR = 4.25; 95% confidence interval (CI), 2.05-8.84], 6 times (RR = 5.69; 95% CI, 2.31-14.00), and 5 times (RR = 5.17; 95% CI, 1.76-15.25) more likely to self-report pain in the same Achilles tendon, patellar tendon, and plantar fascia, respectively. Subanalyses on hypoechogenicity and thickening of tendons yielded the similar findings. These types of ultrasound abnormalities were significantly associated with pain in the Achilles tendon, patellar tendon, and plantar fascia ($P < 0.01$). Relative risks ranged from 4.08 (95% CI, 1.97-8.45; thickening and pain in patellar tendon) to 7.14 (95% CI, 3.39-15.05; thickening and pain in Achilles tendon). Neovascularization also demonstrated significant associations with having pain in all structures ($P < 0.001$). The risk of having pain for athletes demonstrating neovascularization were approximately 10 times (RR = 9.99, 95% CI, 4.54-21.96), 6 times (RR = 6.16, 95% CI, 2.95-12.84), and 19 times (RR = 18.94; 95% CI, 7.39-48.55) higher compared with those without neovascularization in the Achilles tendon, patellar tendon, and plantar fascia, respectively.

Logistic regression models revealed that advanced age was significantly associated with the presence of any Achilles tendon abnormality [OR = 1.30 (1.07-1.60), $P = 0.010$]. Younger age [OR = 0.76 (0.64-0.91), $P = 0.002$] and running [OR = 4.27 (1.34-13.6), $P = 0.014$] or explosive [OR = 5.08 (1.74-14.9), $P = 0.003$] sport participation, compared with aquatic sport participation (= reference category), were significantly associated with patellar tendon abnormality. Advanced age [OR = 1.41 (1.02-1.93), $P = 0.036$] was the only variable significantly associated with plantar fascia abnormality. When examining asymptomatic tendons/fasciae, the similar, significant associations above were found ($P < 0.05$), except that age was no longer significant to planter fascia abnormality ($P = 0.067$). Specific to the presence of neovascularity, BMI [OR = 0.73 (0.57-0.94), $P = 0.014$] was the only factor significantly related to Achilles tendon abnormality. For the patellar tendon, explosive sport

Copyright © 2023 Wolters Kluwer Health, Inc. Unauthorized reproduction of this article is prohibited.

TABLE 1. Demographic Information for Student-Athletes (n = 243)

	n	%	Mean	SD
Age			20.2	1.6
BMI			23.2	2.9
Years in sport			9.5	3.8
Female sex	141	58.0%		
Single-sport athlete	216	88.9%		
Sport				
Baseball	11	4.5%		
Basketball	46	18.9%		
Beach volleyball	11	4.5%		
Cross-country	26	10.7%		
Golf	2	0.8%		
Gymnastics	8	3.3%		
Lacrosse	26	10.7%		
Skiing	5	2.1%		
Soccer	11	4.5%		
Softball	6	2.5%		
Swimming/diving	24	9.9%		
Tennis	5	2.1%		
Track and field	48	19.8%		
Volleyball	14	5.8%		
Current Achilles tendon pain				
Left	14	5.8%		
Right	13	5.3%		
Current patellar tendon pain				
Left	23	9.5%		
Right	18	7.4%		
Current plantar fascia pain				
Left	11	4.5%		
Right	8	3.3%		
Prior surgery				
Achilles (left)	0	0.0%		
Achilles (right)	1	0.4%		
Patellar (left)	7	2.9%		
Patellar (right	9	3.7%		
Plantar fascia (left)	0	0.0%		
Plantar fascia (right)	0	0.0%		

participation [OR = 10.26 (1.30-81.26), P = 0.027] as compared with aquatic sport participation (= reference category) was significantly associated with the presence of neovascularity. There were only 3 cases of plantar fascia neovascularity, with the available sample size of 2 after accounting for missing data in the covariates, which did not allow for building the logistic regression model. Inter-rater reliabilities were performed on 49 subjects, as seen on Figure 3.

DISCUSSION

This study represents the largest sample of collegiate student-athletes systematically analyzed for the prevalence of ultrasound abnormalities in the Achilles tendon, patellar tendon, and plantar fascia. As sonographic abnormalities in the patellar tendon and Achilles tendon have been demonstrated to be associated with future injury,[24] this study provides important insight into this population.

Achilles Tendon Sonographic Abnormalities

Previous studies have analyzed Achilles tendon disorders/injury incidence rates among athletes in specific sports, but few report prevalence of specific sonographic abnormalities or compare different sports.[15,25–28] To the best of our knowledge, this is the only study to analyze sonographic Achilles abnormality among a large group of athletes in various sports. Previous studies[26,29]

Copyright © 2023 Wolters Kluwer Health, Inc. Unauthorized reproduction of this article is prohibited.

TABLE 2. Abnormalities Seen on Sonographic Imaging, n = 243 Athletes or 486 Tendons

	n	Total	%
Any abnormality			
Achilles tendon	49	485	10.1%
Patellar tendon	175	470	37.2%
Plantar fascia	19	486	3.9%
Hypoechogenicity			
Achilles tendon	36	484	7.4%
Patellar tendon	166	468	35.5%
Plantar fascia	16	486	3.3%
Morphologic thickening			
Achilles tendon	25	485	5.2%
Patellar tendon	88	470	18.7%
Plantar fascia	18	486	3.7%
Neovascularity			
Achilles tendon	7	481	1.5%
Patellar tendon	72	466	15.5%
Plantar fascia	5	486	1.0%

Those with prior surgeries or missing data have been excluded.

have focused on specific athlete populations and reported Achilles tendon sonographic abnormalities among those athletes. Our study found that the sports with the highest percentage of sonographic abnormality were athletes in cross-country (28.9%), skiing (20.0%), and beach volleyball (13.6%). No studies were identified that analyzed abnormal Achilles tendon sonographic findings in skiers; however, there were a limited number of studies that reported ultrasound findings for volleyball players[29] and runners.[16,27,30]

Of the 243 athletes analyzed, 11.1% of athletes reported Achilles tendon pain at the time of imaging. This is like Achilles tendinopathy prevalence rates reported in other studies across a wide variety of sports.[31–35] Unsurprisingly, pain was associated with the presence of abnormalities, because symptomatic Achilles tendinopathy is often visualized with ultrasound.[35–37] Neovascularity, which is present commonly in chronic tendinopathy[37] and has been demonstrated to be the most sensitive measure of Achilles tendon pain development,[16] was closely associated with the presence of pre-existing pain. Most studies have been performed on an older population,[38–44] so these data provide new insight into the collegiate population.

Patellar Tendon Sonographic Abnormalities

Abnormalities in the patellar tendon were the most common. Beach volleyball (63.6%), volleyball (57.7%), and basketball (54%) were the sports with the highest percentage of athletes with patellar sonographic abnormalities. Similar to our finding of basketball among the sports with the highest prevalence of abnormal sonographic patellar abnormalities, one cross-sectional study[45] identified basketball players with the highest prevalence of hypoechoic regions on sonography when compared with athletes in cricket, netball, Australian football, and basketball.

There are a number of prospective studies on specific sports with varying sonographic abnormality prevalence rates. One study[46] found a very similar sonographic abnormality rate (63%) of patellar tendons in volleyball players across a competitive season. Another study identified a much lower prevalence of 20.8% patellar tendon abnormality among female collegiate volleyball players. Other studies have reported lower proportions of patellar tendon abnormality in various sports: 26% in elite teenage basketball, 36% in elite junior volleyball players, 26.6% in adult volleyball players, and 33.7% in male collegiate

TABLE 3. Contingency Table on Ultrasound Abnormality and Presence of Pain at the Time of Scan

Tendon	Ultrasound Abnormality	Pain		RR (95% CI)*	*P**
		Yes	No		
Achilles	Yes	9 (17.7)	42 (82.3)	4.25 (2.05-8.84)	**<0.001**
	No	18 (4.2)	416 (95.8)		
Patellar	Yes	27 (15.4)	148 (84.6)	5.69 (2.31-14.00)	**<0.001**
	No	8 (2.7)	287 (97.3)		
Plantar fascia	Yes	3 (17.7)	14 (82.3)	5.17 (1.76-15.25)	**0.003**
	No	16 (3.4)	453 (96.6)		

Values are frequency (%), unless specified otherwise.
** Calculated from the generalized linear model with binomial family and log link using cluster-robust standard errors.*
Bold values signify $p \leq 0.05$.

Copyright © 2023 Wolters Kluwer Health, Inc. Unauthorized reproduction of this article is prohibited.

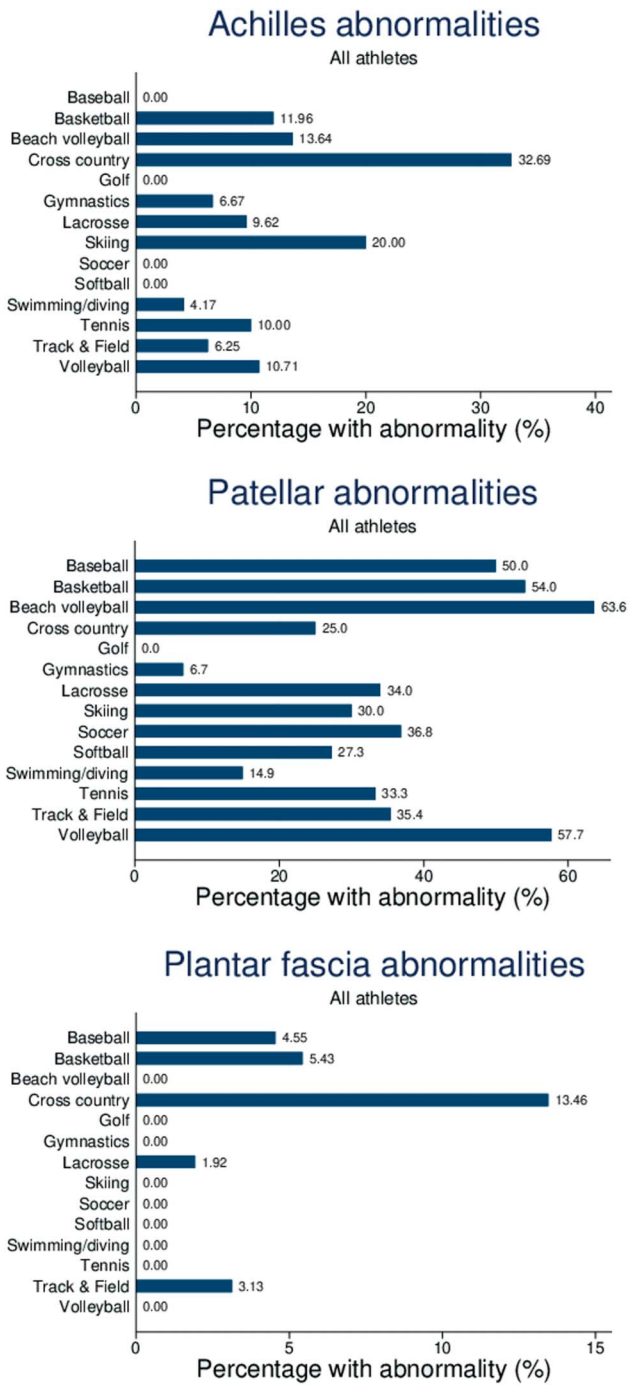

Figure 1. Presence of any sonographic abnormality (hypoechogenicity, thickening, or neovascularity) for (1) Achilles tendon, (2) patellar tendon, and (3) plantar fascia separated by sport. Total n = 485 Achilles tendons, 470 patellar tendons, and 486 plantar fasciae (tendons with prior surgery excluded). Table 1 lists the n within each sport.

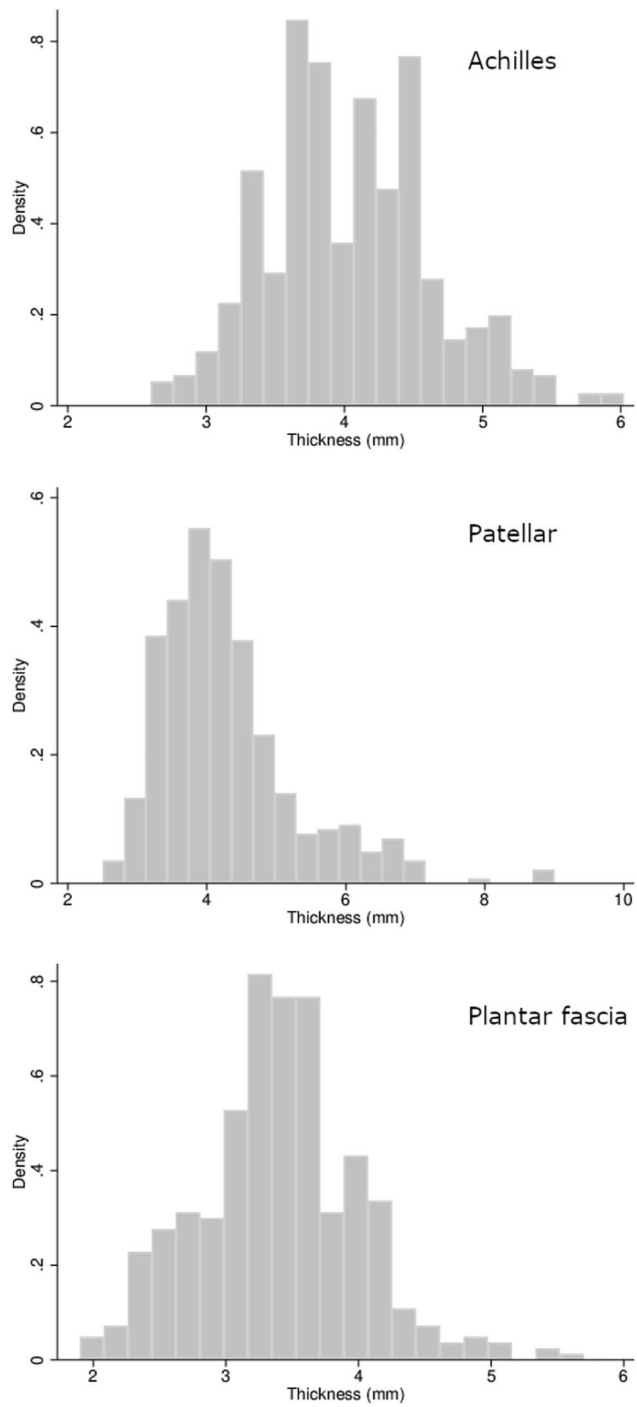

Figure 2. Histogram displaying the range of thickness values for (1) Achilles tendon, (2) patellar tendon, and (3) plantar fascia. Total n = 485 Achilles tendons, 470 patellar tendons, and 486 plantar fasciae (tendons with prior surgery excluded).

basketball players.[47–49] This may be related to differences in abnormality definitions, or may be related to improving ultrasound resolution, in which smaller abnormalities can be more readily identified.

In our study, 16.9% of athletes reported patellar tendon pain at the time of imaging. This finding is similar to a previous study[50] reporting a 14.2% prevalence of jumper's knee among elite athletes.

Hypoechogenicity was seen in 35.5% of all patellar tendons examined with ultrasound. Patellar tendon injuries can be diagnosed with hypoechogenicity on ultrasound[13]; however, morphological changes do not always correlate with clinical symptoms.[51] This study supported these prior findings given that there were a greater number of Achilles tendon sonographic changes compared with athletes with pain at the time of ultrasound examination. Like the Achilles tendon findings

Copyright © 2023 Wolters Kluwer Health, Inc. Unauthorized reproduction of this article is prohibited.

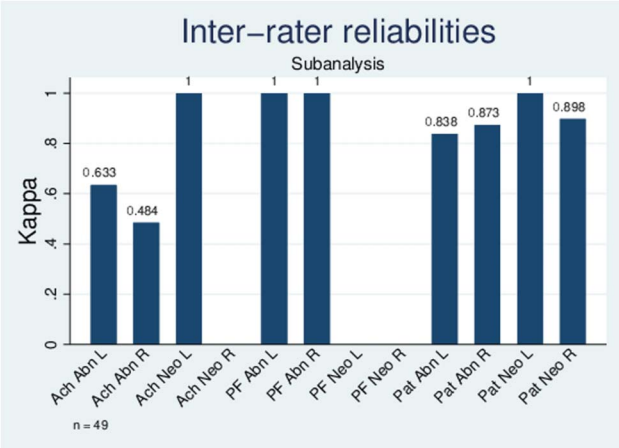

Figure 3. Inter-rater reliabilities (kappa values) for reviewing abnormalities. Missing bars denote all cases scored as absent. Abn, abnormality; Ach, Achilles; PF, plantar fascia; Pat, patellar; L, left; R, right.

and similar to previous studies,[46] neovascularization[46] was associated with pre-existing pain and abnormal patellar sonographic findings.

Plantar Fascia Sonographic Abnormalities

Cross country, basketball, and baseball had the highest percentages of athletes with plantar fascia sonographic abnormalities reported at 17.3%, 5.43%, and 4.55%, respectively. No studies were found that analyzed a large cohort of athletes of various sports and sonographic abnormalities. Previous studies have looked at specific athlete populations such as runners,[9] asymptomatic patients (nonathletes),[52] or those with plantar fascia pain. There was a strong association with plantar fascia pain and sonographic abnormalities. Morphological thickening and hypoechogenicity have been associated with plantar fascia pain in other studies.[53,54] As with Achilles tendon studies, many previous studies[9,54] focused on an older population. Thus, this study provides new information on the collegiate athlete population.[55]

Study Findings

This study identified a correlation between ultrasound abnormalities with the presence of pain, but it is important to note that these correlations were imperfect. Relatively few athletes had pain, and in the case of the plantar fascia, few athletes even had abnormalities. Thus, the positive likelihood of pain with an abnormality remains low. If viewed as a screening tool, this method would not be ideal—asymptomatic abnormalities are more often painless. However, the clinic utility may lie most in this fact; simply because a tendon or fascia is normal, it does not necessarily mean it is "injured." Asymptomatic abnormalities are common, but pain is more commonly associated with abnormalities.

There were strengths and limitations to this study. This was the largest study of its kind to investigate the prevalence of sonographic abnormalities among a large cohort of collegiate student-athletes of various sports. This study also identified risk factors associated with sonographic abnormalities. However, limitations exist. One limitation of this study was that 11.1% of athletes participated in more than one sport. Among these athletes, it is not evident which sport is associated with the sonographic abnormalities and/or pain. Another limitation of this study was that there were more women analyzed than men (58% of study participants were female). Although inter-rater reliability was relatively high, it was not perfect so discrepancies could definitely exist between sonographers. It should be noted that because athletes from many sports were sampled, some sports consisted of low numbers of athletes.

In conclusion, this study completed at 3 Division I institutions is the largest study of its kind to identify the prevalence of sonographic abnormalities in the Achilles tendons, patellar tendons, and plantar fascia among collegiate student-athletes of various sports. The association between sonographic abnormalities and pain provides a basis for improvement in preventative training and rehabilitation and further informs student-athletes and physicians involved in their care.

References

1. Keefer Hutchison M, Patterson C, Cuddeford T, et al. Low prevalence of patellar tendon abnormality and low incidence of patellar tendinopathy in female collegiate volleyball players. *Res Sports Med*. 2020;28:155–167.
2. Sponbeck JK, Hunter I, Neves KA, et al. Achilles tendon single bout and season long adaptations during early and late collegiate cross-country season. *Phys Ther Sport*. 2021;47:114–119.
3. Docking SI, Hart HF, Rio E, et al. Explaining variability in the prevalence of Achilles tendon abnormalities: a systematic review with meta-analysis of imaging studies in asymptomatic individuals. *J Orthop Sports Phys Ther*. 2021;51:232–252.
4. Hannington M, Docking S, Cook J, et al. Self-reported jumpers' knee is common in elite basketball athletes—but is it all patellar tendinopathy? *Phys Ther Sport*. 2020;43:58–64.
5. Fazekas ML, Sugimoto D, Cianci A, et al. Ultrasound examination and patellar tendinopathy scores in asymptomatic college jumpers. *The Physician and Sportsmedicine*. 2018;46:477–484.
6. Sharma P, Maffulli N. Biology of tendon injury: healing, modeling and remodeling. *J Musculoskelet Neuronal Interact*. 2006;6:181–190.
7. Bass E. Tendinopathy: why the difference between tendinitis and tendinosis matters. *Int J Ther Massage Bodywork*. 2012;5:14–17.
8. Stanley LE, Lucero A, Mauntel TC, et al. Achilles tendon adaptation in cross-country runners across a competitive season. *Scand J Med Sci Sports*. 2018;28:303–310.
9. Hall MM, Finnoff JT, Sayeed YA, et al. Sonographic evaluation of the plantar heel in asymptomatic endurance runners. *J Ultrasound Med*. 2015;34:1861–1871.
10. Kudron C, Carlson MJ, Meron A, et al. Using ultrasound measurement of the achilles tendon in asymptomatic runners to assist in predicting tendinopathy. *J Ultrasound Med*. 2020;39:491–496.
11. Docking SI, Rio E, Cook J, et al. Quantification of Achilles and patellar tendon structure on imaging does not enhance ability to predict self-reported symptoms beyond grey-scale ultrasound and previous history. *J Sci Med Sport*. 2019;22:145–150.
12. Sengkerij PM, de Vos R-J, Weir A, et al. Interobserver reliability of neovascularization score using power Doppler ultrasonography in midportion achilles tendinopathy. *Am J Sports Med*. 2009;37:1627–1631.
13. Cook JL, Khan KM, Kiss ZS, et al. Prospective imaging study of asymptomatic patellar tendinopathy in elite junior basketball players. *J Ultrasound Med*. 2000;19:473–479.
14. Cook JL, Khan KM, Kiss ZS, et al. Asymptomatic hypoechoic regions on patellar tendon ultrasound: a 4-year clinical and ultrasound followup of 46 tendons. *Scand J Med Sci Sports*. 2001;11:321–327.
15. Giombini A, Dragoni S, di Cesare A, et al. Asymptomatic Achilles, patellar, and quadriceps tendinopathy: a longitudinal clinical and ultrasonographic study in elite fencers. *Scand J Med Sci Sports*. 2013;23:311–316.
16. Hirschmüller A, Frey V, Konstantinidis L, et al. Prognostic value of Achilles tendon Doppler sonography in asymptomatic runners. *Med Sci Sports Exerc*. 2012;44:199–205.

Copyright © 2023 Wolters Kluwer Health, Inc. Unauthorized reproduction of this article is prohibited.

17. Nishida Y, Nishino T, Tanaka K, et al. An objective measure of patellar tendon thickness based on ultrasonography and MRI in university athletes. *J Clin Med*. 2021;10:4092.
18. McCullagh P, Nelder JA. *Generalized Linear Models*. 2nd ed. London, United Kingdom: Chapman & Hall/CRC; 1989.
19. Hardin JW, Hilbe JM. *Generalized Linear Models and Extensions*. 4th ed. College Station, TX: Stata Press; 2018.
20. Cummings P. Methods for estimating adjusted risk ratios. *Stata J Promoting Commun Stat Stata*. 2009;9:175–196.
21. Wacholder S. Binomial regression in glim: estimating risk ratios and risk differences. *Am J Epidemiol*. 1986;123:174–184.
22. Rogers W. Regression standard errors in clustered samples. *Stata Technical Bulletin* 1994;3:2–30.
23. Williams RL. A note on robust variance estimation for cluster-correlated data. *Biometrics*. 2000;56:645–646.
24. McAuliffe S, McCreesh K, Culloty F, et al. Can ultrasound imaging predict the development of Achilles and patellar tendinopathy? A systematic review and meta-analysis. *Br J Sports Med*. 2016;50: 1516–1523.
25. Chan JJ, Chen KK, Sarker S, et al. Epidemiology of Achilles tendon injuries in collegiate level athletes in the United States. *Int Orthop*. 2020; 44:585–594.
26. Fredberg U, Bolvig L. Significance of ultrasonographically detected asymptomatic tendinosis in the patellar and achilles tendons of elite soccer players: a longitudinal study. *Am J Sports Med*. 2002;30:488–491.
27. Ooi C-C, Schneider ME, Malliaras P, et al. Sonoelastography of the achilles tendon: prevalence and prognostic value among asymptomatic elite Australian rules football players. *Clin J Sport Med*. 2016;26: 299–306.
28. Fredberg U, Bolvig L, Andersen NT. Prophylactic training in asymptomatic soccer players with ultrasonographic abnormalities in Achilles and patellar tendons: the Danish Super League Study. *Am J Sports Med*. 2008;36:451–460.
29. Balaban M, Idilman IS, Ipek A, et al. Elastographic findings of achilles tendons in asymptomatic professional male volleyball players. *J Ultrasound Med*. 2016;35:2623–2628.
30. Cushman DM, Petrin Z, Eby S, et al. Ultrasound evaluation of the patellar tendon and Achilles tendon and its association with future pain in distance runners. *Phys Sportsmed*. 2021;49:410–419.
31. Emerson C, Morrissey D, Perry M, et al. Ultrasonographically detected changes in Achilles tendons and self reported symptoms in elite gymnasts compared with controls–an observational study. *Man Ther*. 2010;15: 37–42.
32. Kader D, Saxena A, Movin T, et al. Achilles tendinopathy: some aspects of basic science and clinical management. *Br J Sports Med*. 2002;36: 239–249.
33. Lopes AD, Hespanhol LC, Yeung SS, et al. What are the main running-related musculoskeletal injuries? A Systematic Review. *Sports Med*. 2012; 42:891–905.
34. Kakouris N, Yener N, Fong DTP. A systematic review of running-related musculoskeletal injuries in runners. *J Sport Health Sci*. 2021;10:513–522.
35. Järvinen TAH, Kannus P, Maffulli N, et al. Achilles tendon disorders: etiology and epidemiology. *Foot Ankle Clin*. 2005;10:255–266.
36. Harris CA, Peduto AJ. Achilles tendon imaging. *Australas Radiol*. 2006; 50:513–525.
37. Aström M, Gentz CF, Nilsson P, et al. Imaging in chronic achilles tendinopathy: a comparison of ultrasonography, magnetic resonance imaging and surgical findings in 27 histologically verified cases. *Skeletal Radiol*. 1996;25:615–620.
38. Longo UG, Berton A, Stelitano G, et al. 2017 marathon of rome: anthropometry and sport profile in 350 runners and association with achilles and patellar tendinopathy. *Clin J Sport Med*. 2021;31:e15–e20.
39. Longo UG, Rittweger J, Garau G, et al. Patellar tendinopathy in master track and field athletes: influence of impact profile, weight, height, age and gender. *Knee Surg Sports Traumatol Arthrosc*. 2011;19:508–512.
40. Longo UG, Rittweger J, Garau G, et al. No influence of age, gender, weight, height, and impact profile in achilles tendinopathy in masters track and field athletes. *Am J Sports Med*. 2009;37:1400–1405.
41. Shaikh Z, Perry M, Morrissey D, et al. Achilles tendinopathy in club runners. *Int J Sports Med*. 2012;33:390–394.
42. Zanetti M, Metzdorf A, Kundert H-P, et al. Achilles tendons: clinical relevance of neovascularization diagnosed with power Doppler US. *Radiology*. 2003;227:556–560.
43. Lysholm J, Wiklander J. Injuries in runners. *Am J Sports Med*. 1987;15: 168–171.
44. Kannus P, Niittymäki S, Järvinen M, et al. Sports injuries in elderly athletes: a three-year prospective, controlled study. *Age Ageing*. 1989;18: 263–270.
45. Cook JL, Khan KM, Harcourt PR, et al. Patellar tendon ultrasonography in asymptomatic active athletes reveals hypoechoic regions: a study of 320 tendons. Victorian Institute of Sport Tendon Study Group. *Clin J Sport Med*. 1998;8:73–77.
46. Cook JL, Malliaras P, de Luca J, et al. Vascularity and pain in the patellar tendon of adult jumping athletes: a 5 month longitudinal study * Commentary. *Br J Sports Med*. 2005;39:458–461.
47. Cook JL, Khan KM, Kiss ZS, et al. Patellar tendinopathy in junior basketball players: a controlled clinical and ultrasonographic study of 268 patellar tendons in players aged 14-18 years. *Scand J Med Sci Sports*. 2000;10:216–220.
48. Gisslén K, Gyulai C, Nordström P, et al. Normal clinical and ultrasound findings indicate a low risk to sustain jumper's knee patellar tendinopathy: a longitudinal study on Swedish elite junior volleyball players. *Br J Sports Med*. 2007;41:253–258.
49. Malliaras P. Prospective study of change in patellar tendon abnormality on imaging and pain over a volleyball season. *Br J Sports Med*. 2006;40: 272–274.
50. Lian OB, Engebretsen L, Bahr R. Prevalence of jumper's knee among elite athletes from different sports: a cross-sectional study. *Am J Sports Med*. 2005;33:561–567.
51. Kulig K, Landel R, Chang Y-J, et al. Patellar tendon morphology in volleyball athletes with and without patellar tendinopathy. *Scand J Med Sci Sports*. 2013;23:e81–e88.
52. Gadalla N, Kichouh M, Boulet C, et al. Sonographic evaluation of the plantar fascia in asymptomatic subjects. *J Belgian Soc Radiol*. 2014;97: 271–273.
53. Salehi S, Shadmehr A, Olyaei G, et al. Ultrasonographic measurements of plantar fascia thickness and echogenicity in individuals with and without plantar fasciitis: reliability and group differences. *Foot (Edinb)*. 2021;49: 101849.
54. Tsai WC, Chiu MF, Wang CL, et al. Ultrasound evaluation of plantar fasciitis. *Scand J Rheumatol*. 2000;29:255–259.
55. Radwan A, Wyland M, Applequist L, et al. Ultrasonography, an effective tool in diagnosing plantar fasciitis: a systematic review of diagnostic trials. *Int J Sports Phys Ther*. 2016;11:663–671.

Copyright © 2023 Wolters Kluwer Health, Inc. Unauthorized reproduction of this article is prohibited.